

Letters to the Editor

NEUROSURGICAL FORUM

CSF leak in transsphenoidal surgery

TO THE EDITOR: We read with great interest the article by Mehta and Oldfield² (Mehta GU, Oldfield EH: Prevention of intraoperative cerebrospinal fluid leaks by lumbar cerebrospinal fluid drainage during surgery for pituitary macroadenomas. *J Neurosurg* 116:1299–1303, June 2012). The authors investigated the role of lumbar drainage in transsphenoidal surgery, comparing the results of 114 operations without an intraoperative CSF drain to 44 cases in which a lumbar subarachnoid catheter was placed before surgery to drain CSF at the time of tumor removal. The intraoperative CSF leak rate was significantly lower when the spinal drain was used; the postoperative CSF leak rate was the same (5%) in the both groups. The authors' conclusion is that intraoperative CSF drainage is useful, low risk, and obviates the need for sellar repair by lowering the intraoperative incidence of CSF leakage.

The article is of great interest because it provides new data to add to the ongoing discussion on the use of CSF drainage in transsphenoidal surgery. Most advocates stress the usefulness of lowering intracranial pressure (ICP) to allow a definitive sealing of the subarachnoid space; opponents underline the possible risks of lumbar drainage and the lack of clear indications for it. The authors support its use because it lowers the incidence of intraoperative CSF leaks and therefore diminishes the need of sellar reconstruction. Examining the article's data, though, this conclusion does not seem to be supported; furthermore, some data, which would add even more value to the paper, are missing.

The most important clinical outcome reported by Mehta and Oldfield is that the rate of postoperative CSF leak does not decrease in the group with intraoperative drainage compared to the group without it; the rate was 5% in both groups. This might have two possible explanations: 1) the evidence of intraoperative CSF leaks in patients with lumbar drain is underestimated because of CSF diversion during surgery; 2) although the incidence of intraoperative CSF leaks is really lower, some other factors lead to postoperative leakage. The authors do not dwell on sellar packing, but they report that sellar reconstruction was performed less frequently when CSF diversion was used intraoperatively. Could this be the reason for the postoperative CSF leak? In Fig. 1 of their paper, the authors depict the physiopathogenesis of low-flow CSF leaks in transsphenoidal surgery: the removal of a macroadenoma leads to the descent of the suprasellar arachnoid, which then

“weeps.” If sellar reconstruction is not performed in these cases, one could assume that a Valsalva maneuver (e.g., during extubation, coughing, or sneezing) might breach the arachnoid that is not supported. We could then interpret the reported data as support for sellar reconstruction rather than for CSF diversion (Fig. 1). This was indeed the case in our clinical practice: When we were not systematically using sellar packing with the endoscopic approach, we observed a postoperative CSF leak in a patient in whom no intraoperative CSF leakage occurred; postoperatively, the patient developed pneumonia, with persistent coughing, and subsequent evidence of a CSF leak.

In other words, if the incidence of postoperative CSF leakage is the same regardless of whether we use an intra-

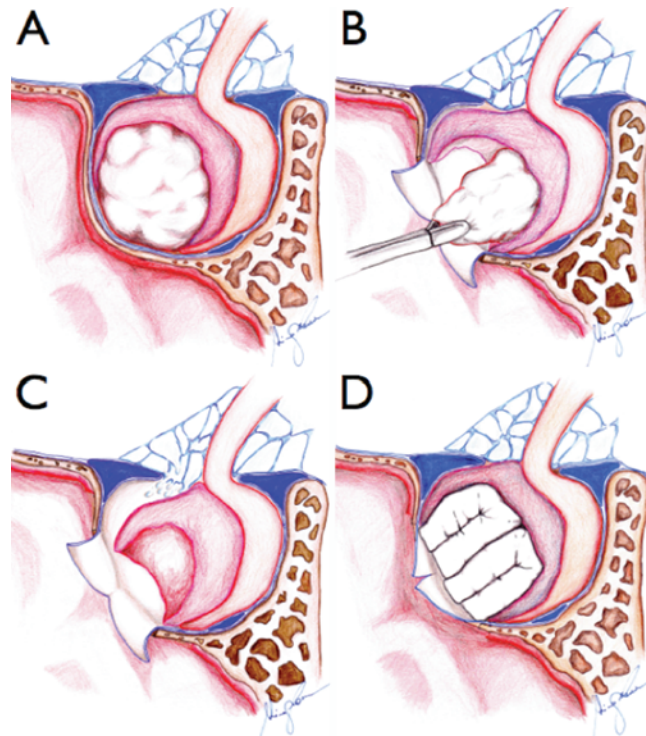


FIG. 1. Artist's renderings of macroadenoma removal. Once the macroadenoma has been removed, normal ICP causes a descent of the suprasellar arachnoid in the sella (**A and B**). If no packing is used (**C**), there is an increased risk of postoperative CSF leakage, especially if the ICP is increased. If sellar packing is used (**D**), the breach of the suprasellar arachnoid might be less likely because the ICP is counterbalanced by the packing itself. Copyright Francesco Doglietto. Published with permission. Figure is available in color online only.

operative CSF drain or not, could we hypothesize that the advantage of CSF diversion was lost due to decreased sellar reconstruction? This would be a noteworthy conclusion, as many authors do not perform any sellar reconstruction when no CSF leak is evident.^{1,3}

It would also be interesting to provide other data for this population, which are possibly taken for granted, but would add support to the authors' conclusions. Was the tumor removal rate the same for both groups? One might question the maneuver of intraoperatively lowering the CSF leak pressure because it might decrease the chance of tumor removal.

Finally, we would like to thank the authors for their contribution: the paper has the merit of providing significant data to the ongoing debate about the role of intra- and postoperative CSF diversion in transsphenoidal surgery from a study that would be difficult to perform in most centers.

Francesco Doglietto, MD, PhD
Andrea Bolzoni Villaret, MD
Roberto Stefani, MD
Piero Nicolai, MD
Marco Maria Fontanella, MD
 University of Brescia, Brescia, Italy
Giorgio Lofrese, MD
Giulio Maira, MD
 Catholic University of Rome, Rome, Italy

ACKNOWLEDGMENT

We would like to thank Adriano Francione, MD, for Fig. 1.

DISCLOSURE

The authors report no conflict of interest.

References

1. Cappabianca P, Cavallo LM, Esposito F, Valente V, De Divitiis E: Sellar repair in endoscopic endonasal transsphenoidal surgery: results of 170 cases. *Neurosurgery* **51**:1365–1372, 2002
2. Mehta GU, Oldfield EH: Prevention of intraoperative cerebrospinal fluid leaks by lumbar cerebrospinal fluid drainage during surgery for pituitary macroadenomas. *J Neurosurg* **116**:1299–1303, 2012
3. Sonnenburg RE, White D, Ewend MG, Senior B: Sellar reconstruction: is it necessary? *Am J Rhinol* **17**:343–346, 2003

Response

Intraoperative CSF leaks are encountered frequently during surgery for pituitary macroadenomas, often require additional surgery of various types for repair, and can lead to postoperative CSF leakage.² In 2012, we reported the results of a study using lumbar CSF drain placement after general anesthesia, just before beginning surgery, and CSF drainage during surgery to prevent CSF leaks during resection of pituitary macroadenomas. When compared with similar patients who had surgery before this protocol was instituted, we found that intraoperative CSF drainage reduced the rate of CSF leaks during surgery for macroadenomas with suprasellar extension, from 57% to 5% ($p < 0.001$). This, in turn, diminished the need to perform a fat graft harvest to repair an intraoperative CSF leak or post-

operative lumbar drainage to prevent a postoperative leak. This reduction in the need to perform additional surgery or subject the patients to prolonged CSF drainage and bed rest was the principal benefit of this protocol, as we did not find a difference in the rates of postoperative CSF leaks between groups (5% in each).

We appreciate the interest of Doglietto and colleagues in our report. In their letter, they emphasize this last finding that no change in the rate of postoperative CSF leak occurred. We respectfully disagree with their, not our, interpretation that this was “the most important clinical outcome.” Rather, our study was specifically designed to test the effect of CSF drainage on intraoperative CSF leaks. Moreover, in our study it was not appropriate to reach a conclusion based on only the two instances of postoperative CSF leak in patients with intraoperative CSF drainage because, even had there been no postoperative CSF leaks in this group, our study was not powered to prove a difference ($p = 0.32$, Fisher's exact test).

Doglietto and colleagues state that we indicate that the use of intraoperative CSF drainage “obviates the need for sellar repair by lowering the intraoperative incidence of CSF leakage,” that we “report that sellar reconstruction was performed less frequently when CSF diversion was used intraoperatively,” and suggest that a lack of sellar floor repair in the group with CSF drainage may explain the two postoperative CSF leaks. We did not make those statements, and do not now. As we stated in the *Methods* section of that report, “The surgical technique, including methods of sellar floor repair and observations during surgery leading to sellar floor repair, was uniform throughout all stages of the study.” We agree that after surgery for macroadenomas downward relaxation of the diaphragma sella could result in a persistent CSF fistula, and in cases with a large defect of the anterior face and floor of the sella, reconstruction of the sella face and floor may be necessary. Most patients in both groups, with or without intraoperative CSF drainage, underwent reconstruction of the sella. In most cases a small portion of gelatin sponge was placed within the sella to prevent extreme downward prolapse of the remaining sella contents and the diaphragm sella, and bone harvested during the approach, or a porous polyethylene implant, was used to reconstruct the anterior face and floor of the sella. In most cases a synthetic hydrogel was used to keep this reconstruction in place.

Finally, preoperative CSF drainage did not affect the rate of gross-total resection. With the operating microscope we typically visualize the suprasellar contents and the diaphragm with a Valsalva maneuver and do so despite intraoperative CSF drainage. As reported by Dallapiazza et al., by using the techniques that we describe, the rate of gross-total resection (83% documented by MRI at 1 year) of nonfunctioning adenomas (Knosp Grade 2 or less) was similar to that of the purely endoscopic approach performed by an experienced and skilled endoscopic pituitary surgeon.¹

Gautam U. Mehta, MD

National Institute of Neurological Disorders and Stroke, Bethesda, MD

Edward H. Oldfield, MD

University of Virginia Health Sciences Center, Charlottesville, VA

References

1. Dallapiazza R, Bond AE, Grober Y, Louis RG, Payne SC, Oldfield EH, et al: Retrospective analysis of a concurrent series of microscopic versus endoscopic transsphenoidal surgeries for Knosp Grades 0–2 nonfunctioning pituitary macroadenomas at a single institution. **J Neurosurg** **121**:511–517, 2014
2. Kaptain GJ, Kanter AS, Hamilton DK, Laws ER: Management and implications of intraoperative cerebrospinal fluid leak in transnasoseptal transsphenoidal microsurgery. **Neurosurgery** **68** (1 Suppl Operative):ons144–ons151, 2011

INCLUDE WHEN CITING

Published online August 28, 2015; DOI: 10.3171/2014.11.JNS142480.

©AANS, 2015